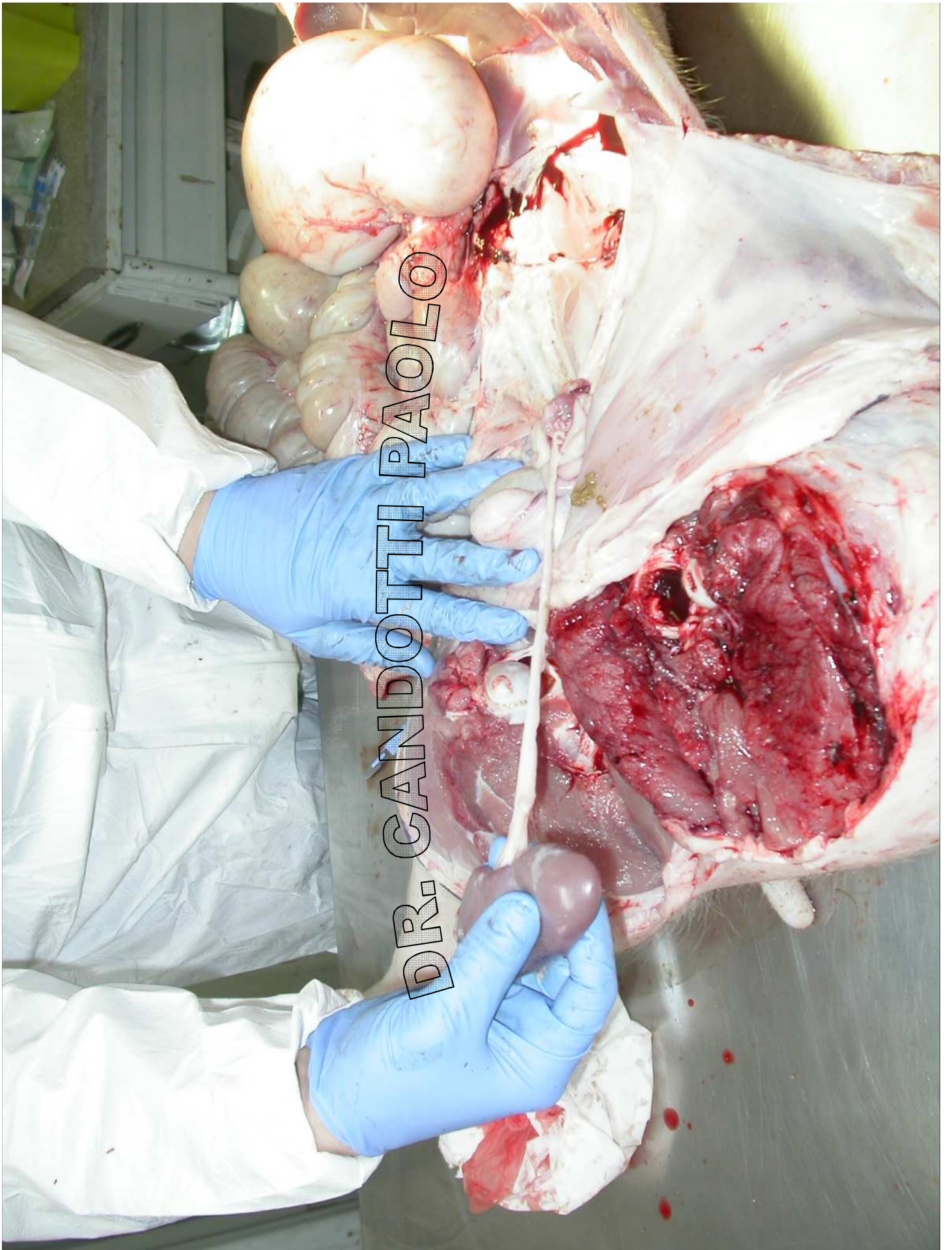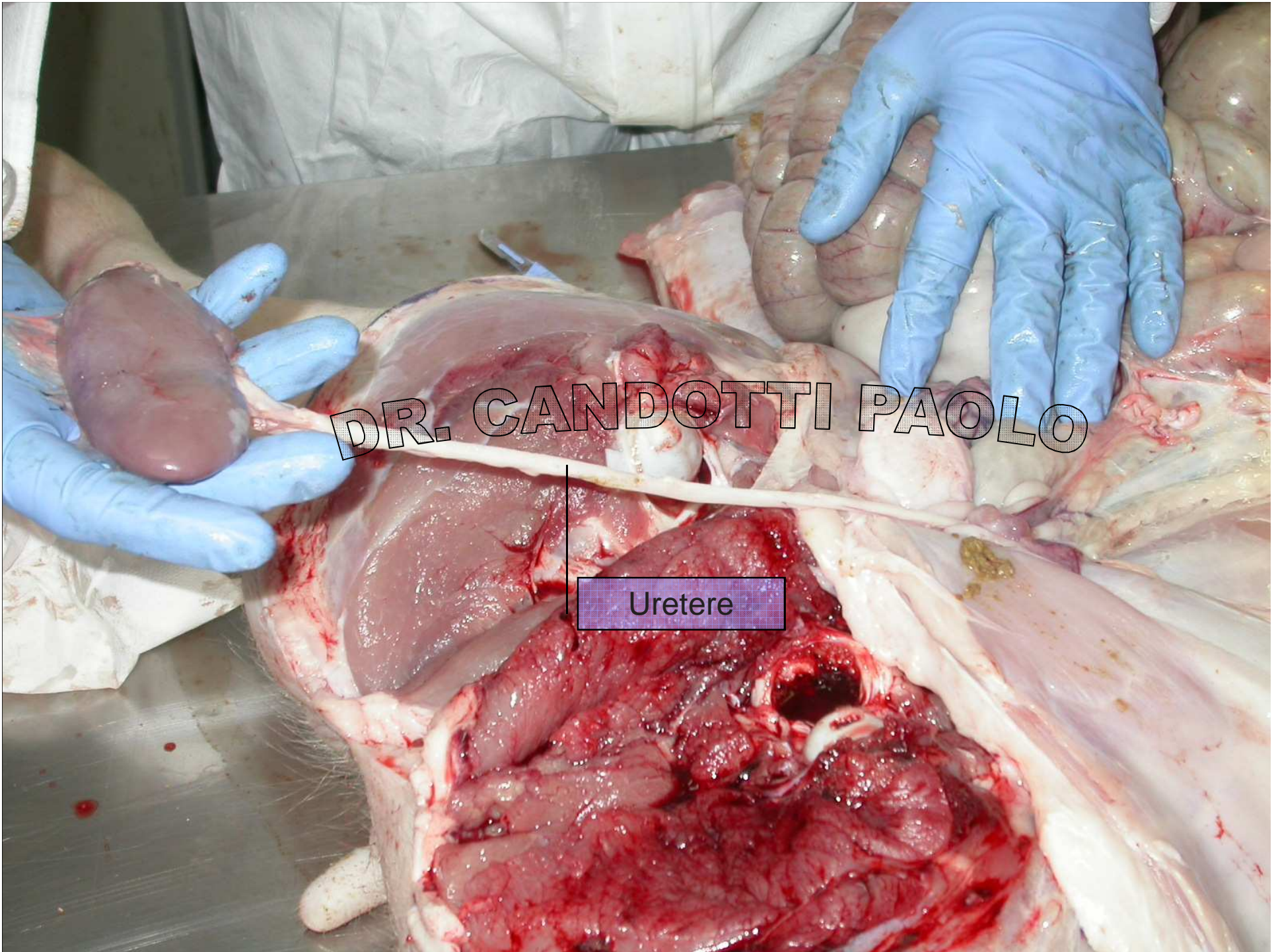


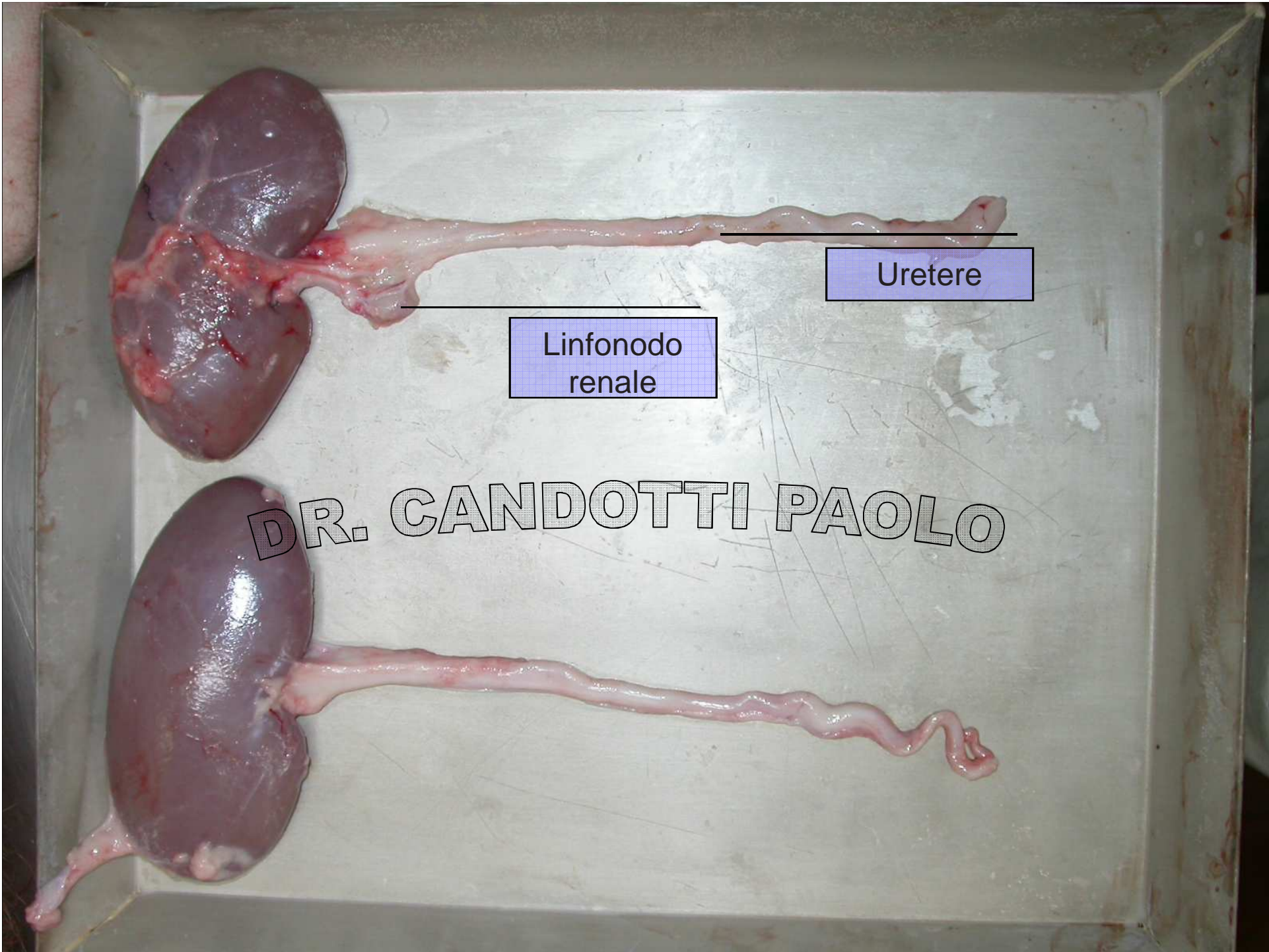
DR. CANDOTTI PAOLO





DR. CANDOTTI PAOLO

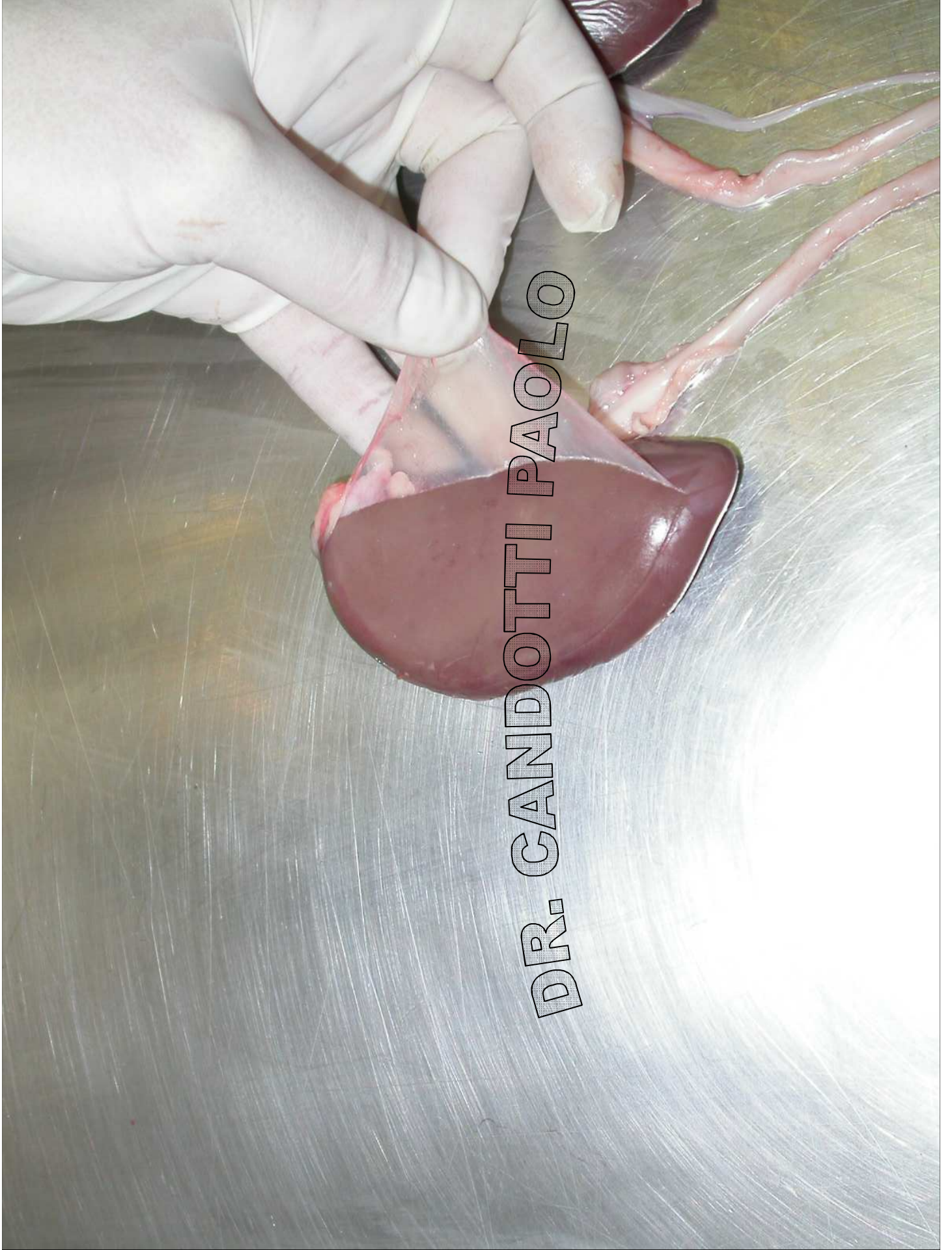Uretere



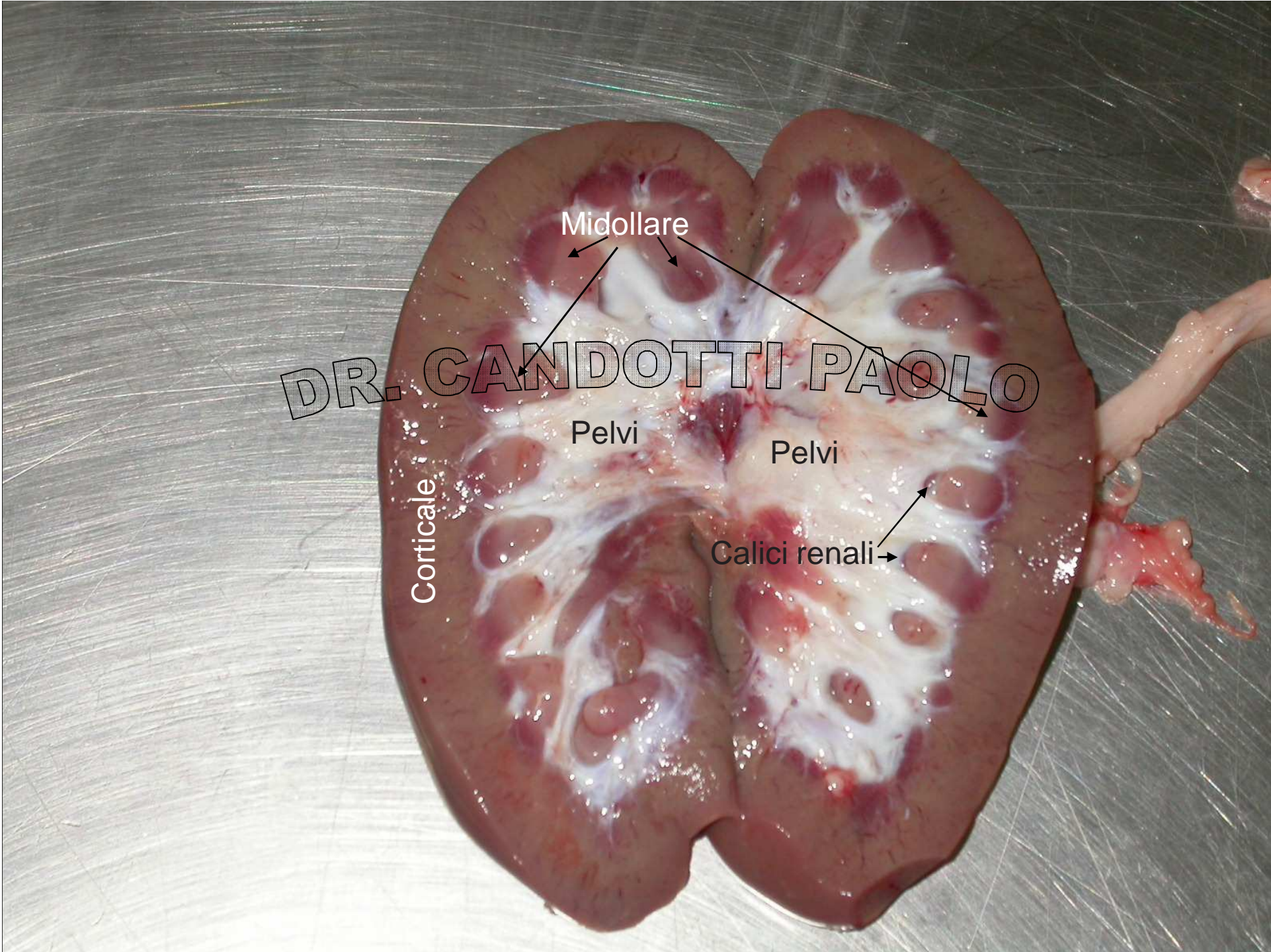
Uretere

Linfonodo
renale

DR. CANDOTTI PAOLO



DR. CANDOTTI PAOLO



Midollare

DR. CANDOTTI PAOLO

Pelvi

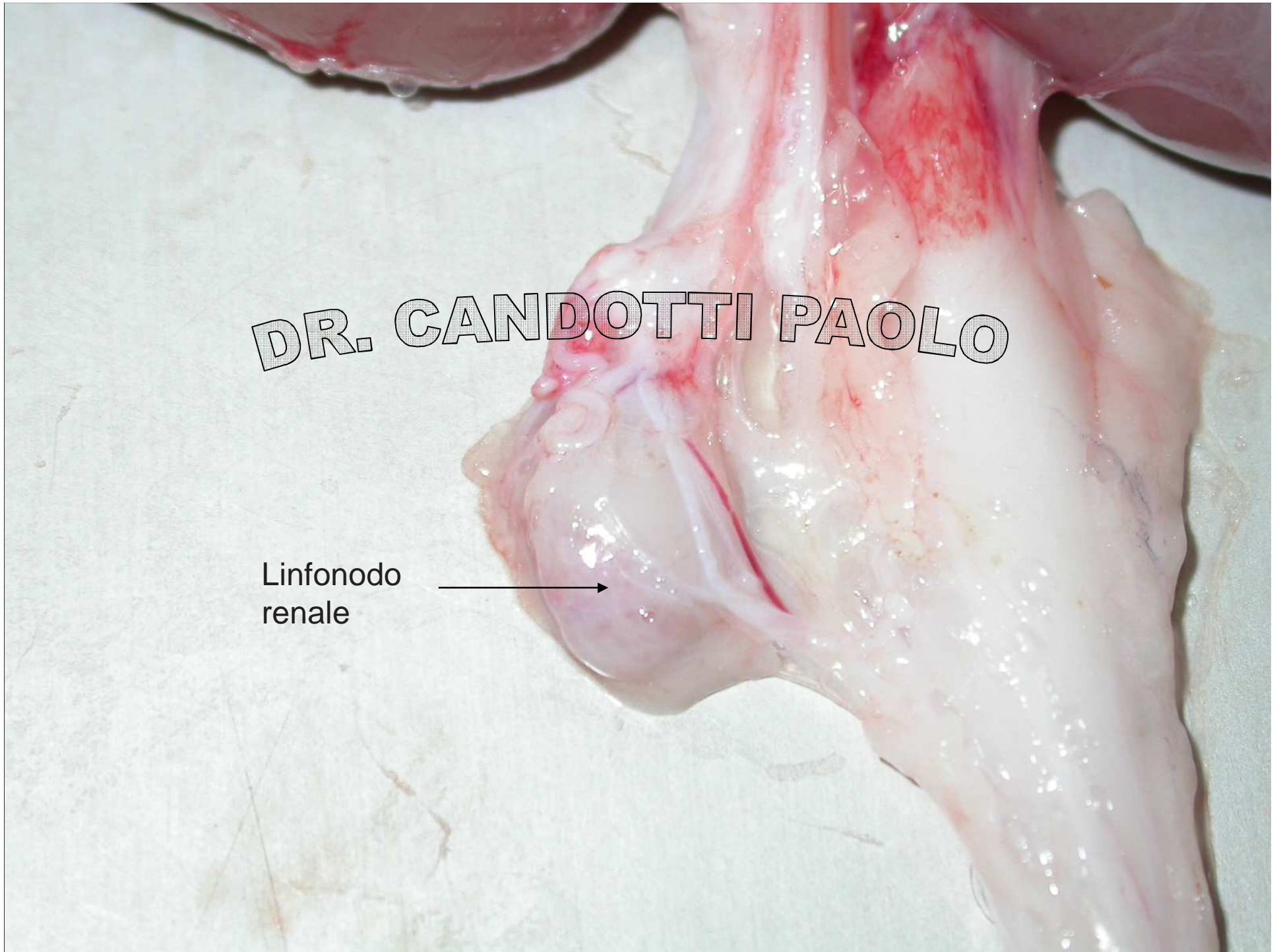
Pelvi

Corticale

Calici renali

DR. CANDOTTI PAOLO

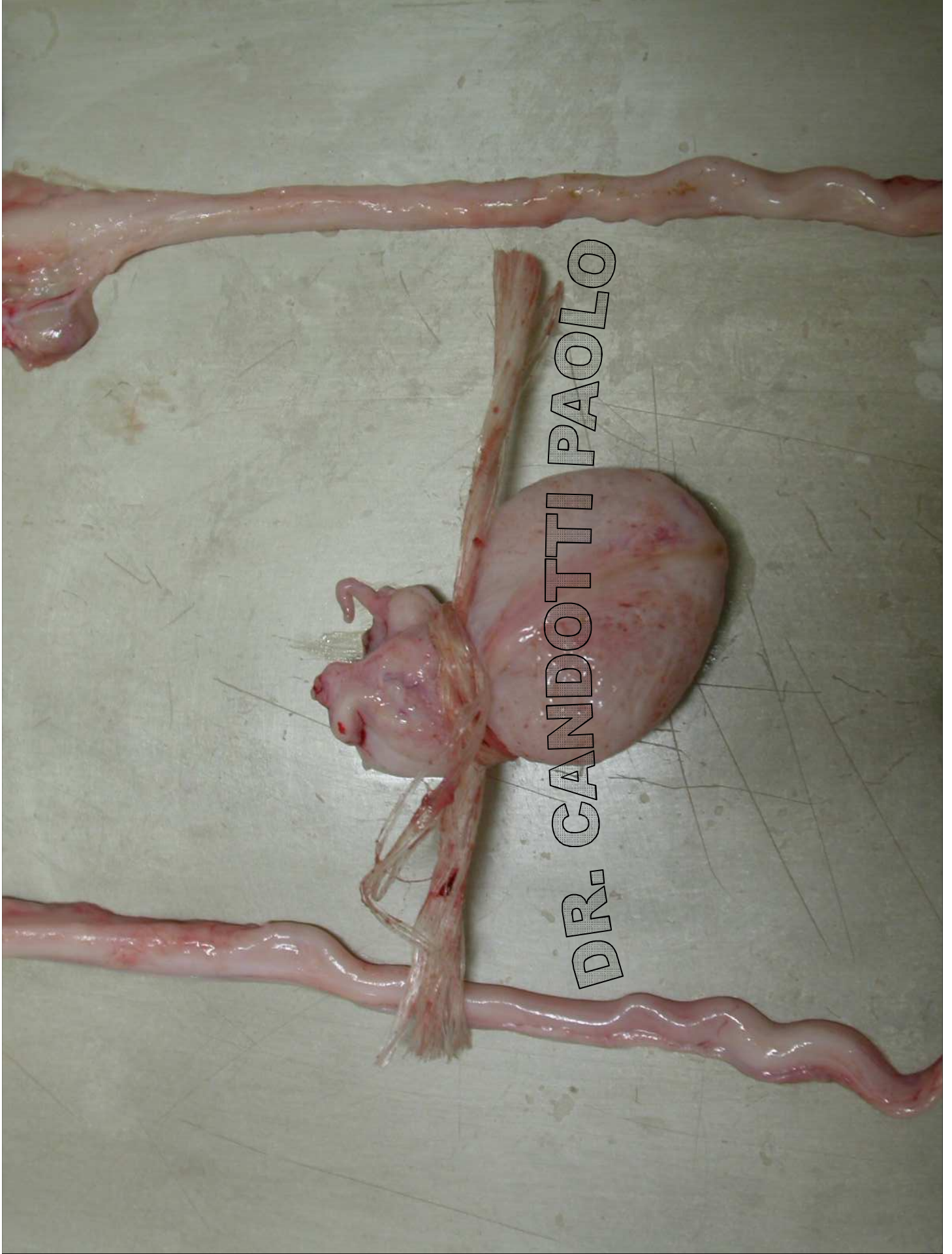Linfonodo
renale



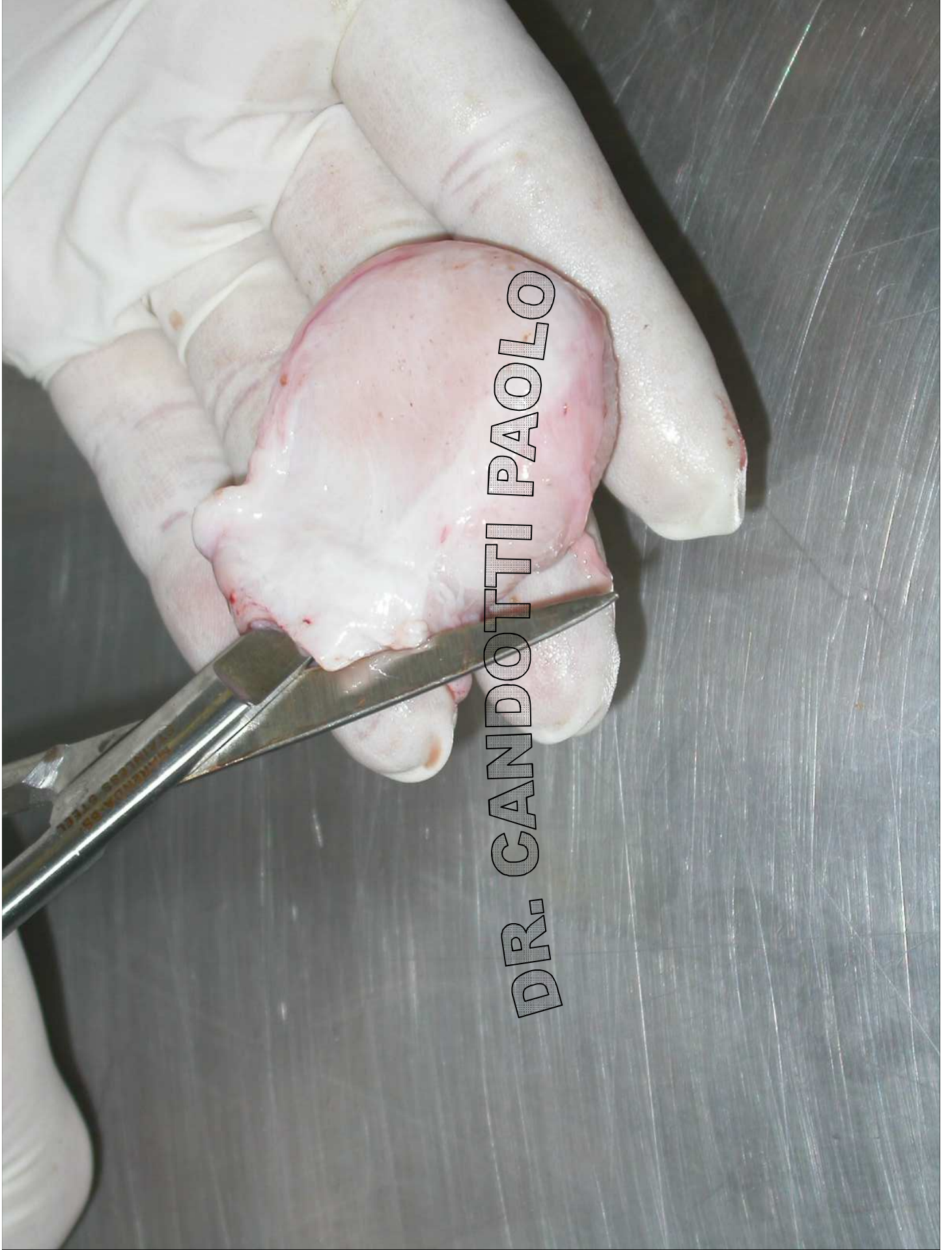A surgical dissection of the bladder neck. The image shows a large, reddish, lobulated mass, likely a tumor, being removed from the bladder. The surrounding tissue is yellowish and fatty. A gloved hand is visible, holding a surgical instrument. The text "DR. CANDOTTI PAOLO" is overlaid on the image.

DR. CANDOTTI PAOLO

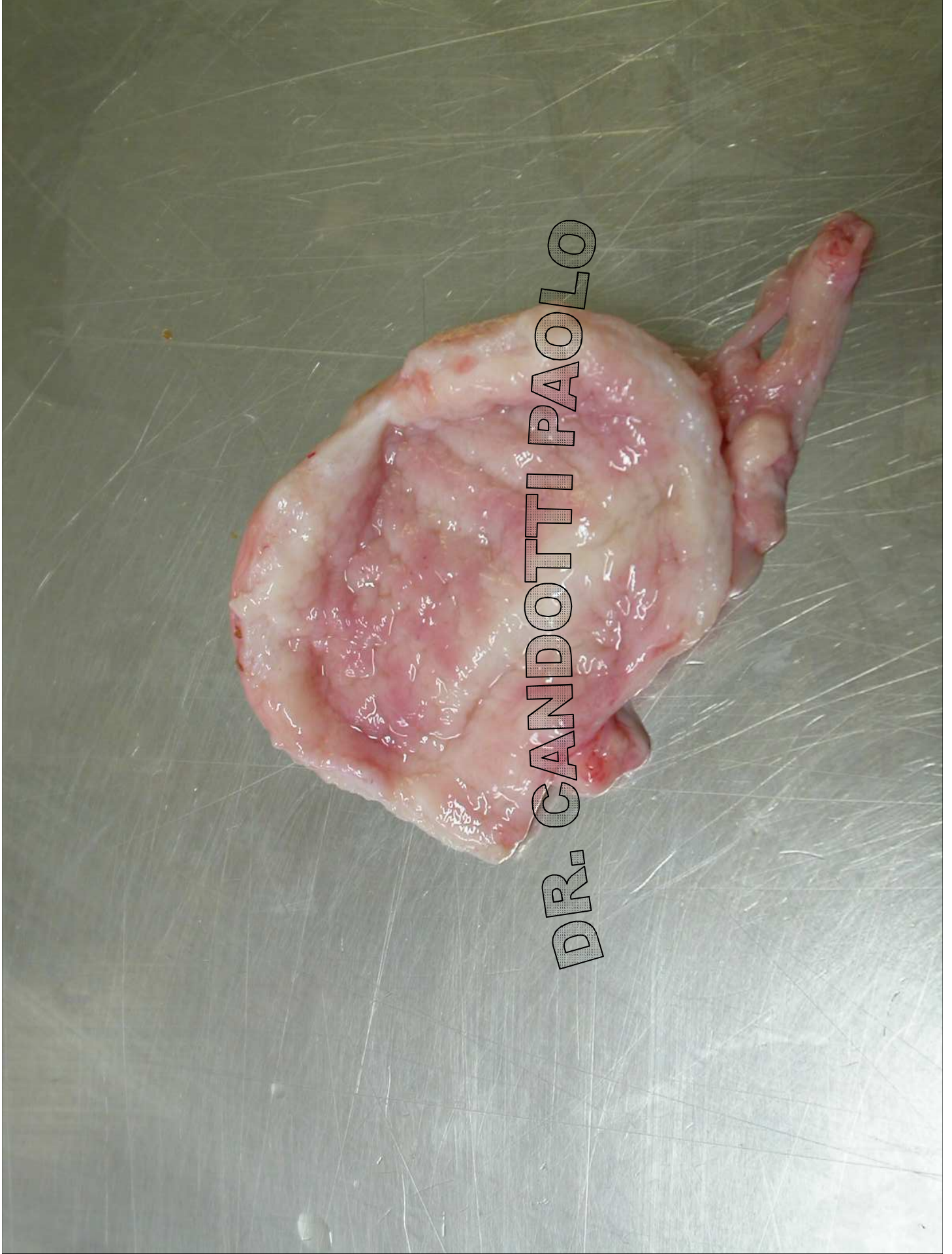Collo della
vescica



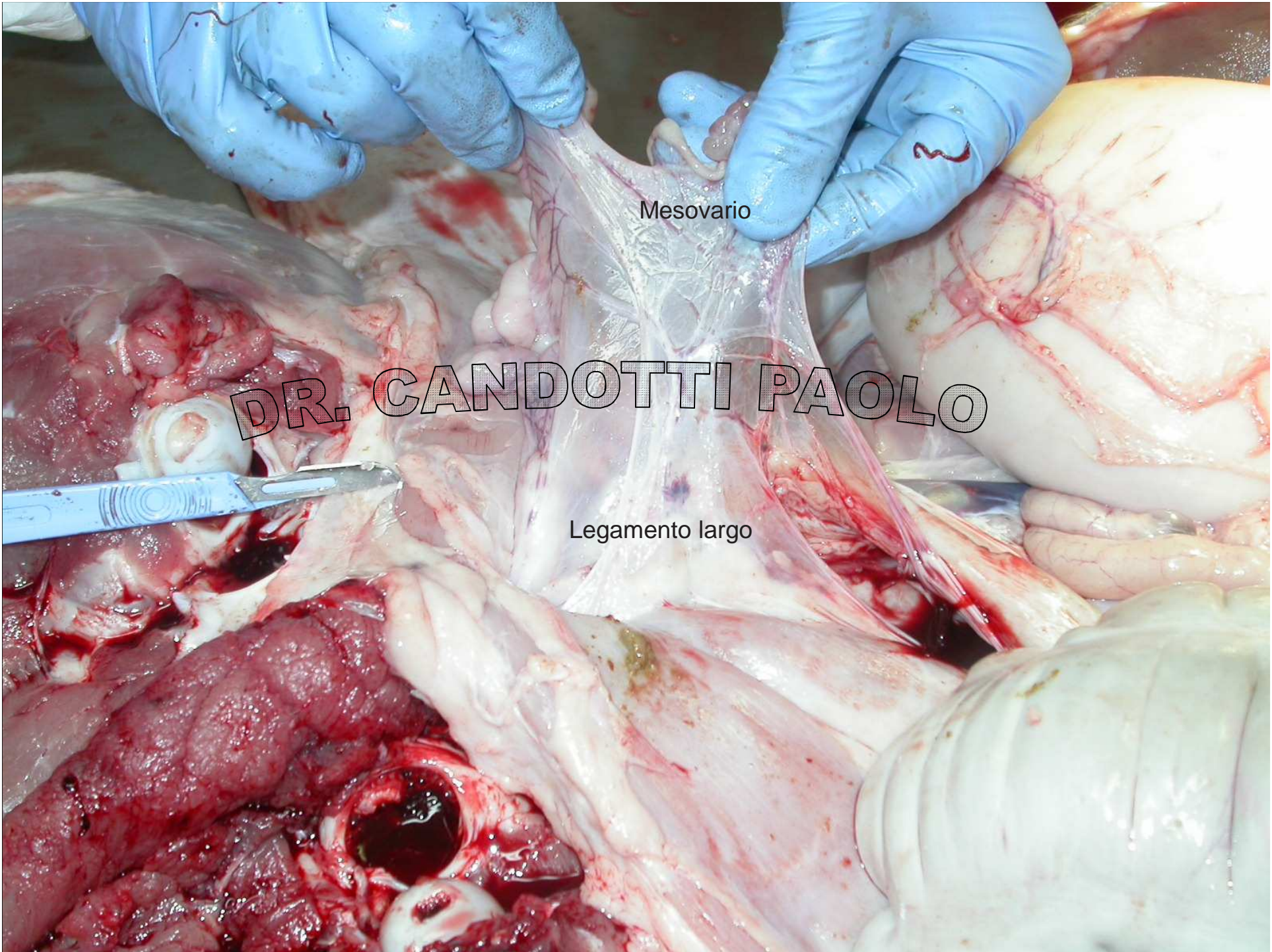
DR. CANDOTTI PAOLO



DR. CANDOTTI PAOLO



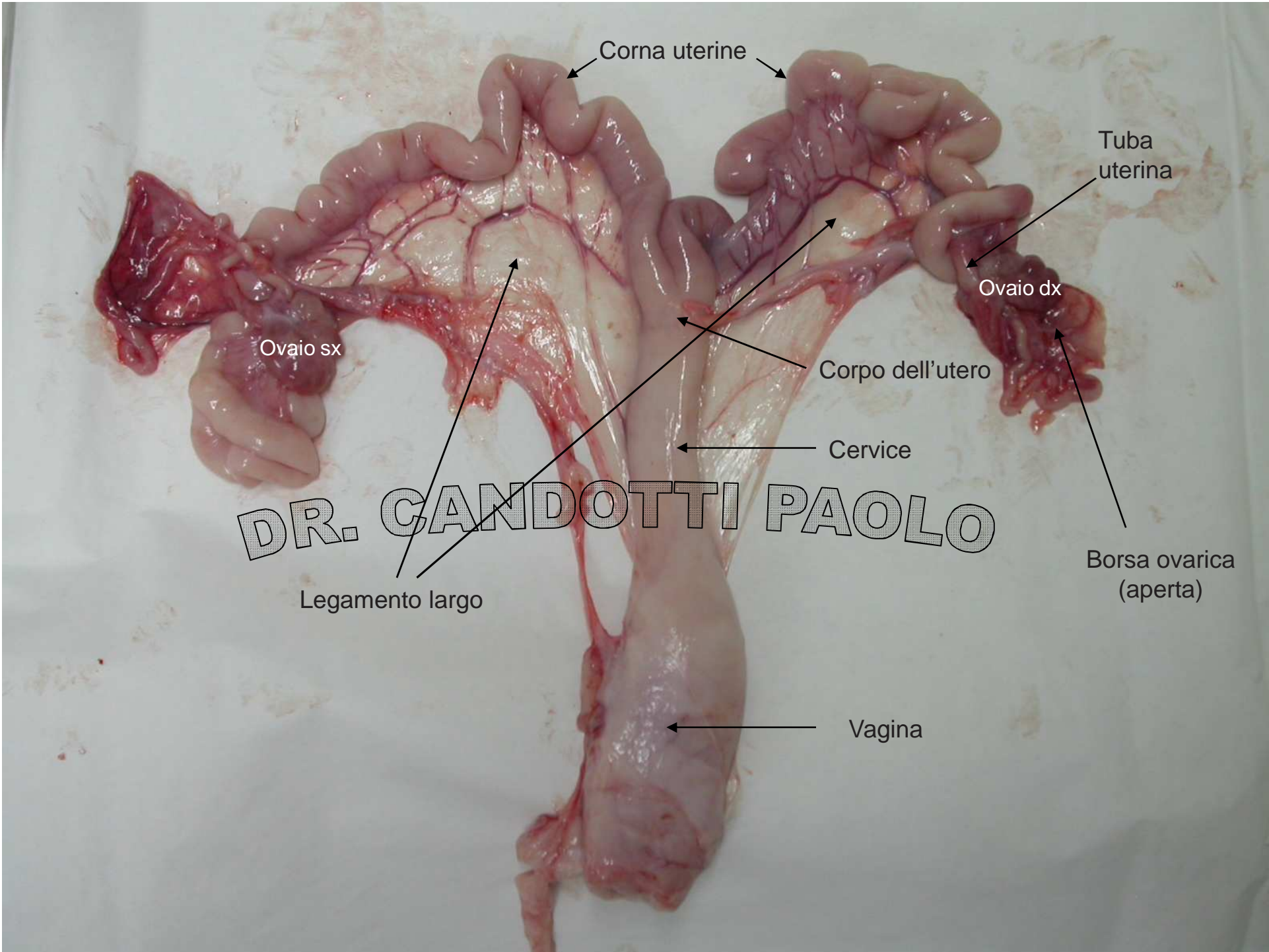
DR. CANDOTTI PAOLO



Mesovario

DR. CANDOTTI PAOLO

Legamento largo



Corna uterine

Tuba uterina

Ovaio dx

Ovaio sx

Corpo dell'utero

Cervice

DR. CANDOTTI PAOLO

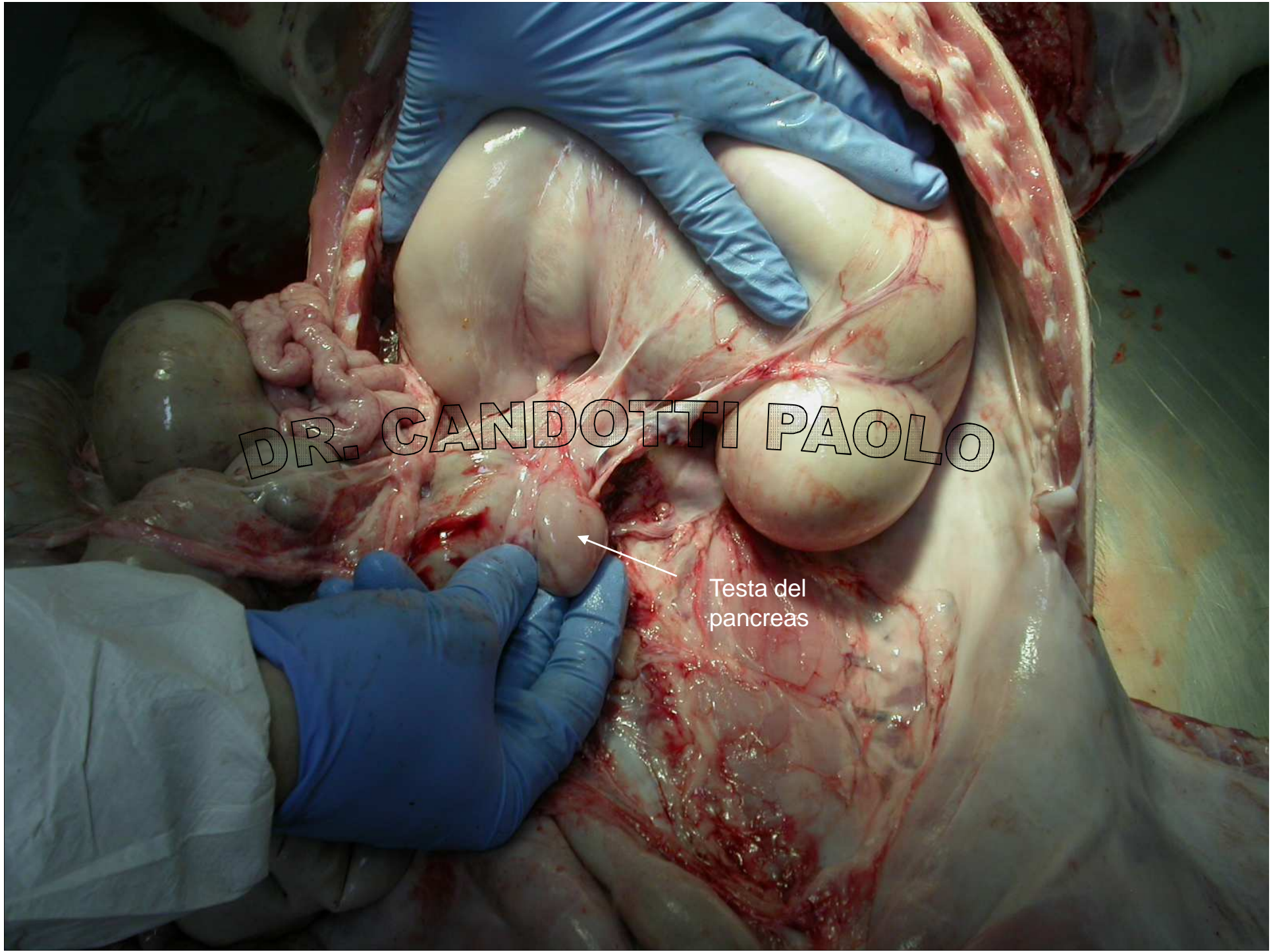
Legamento largo

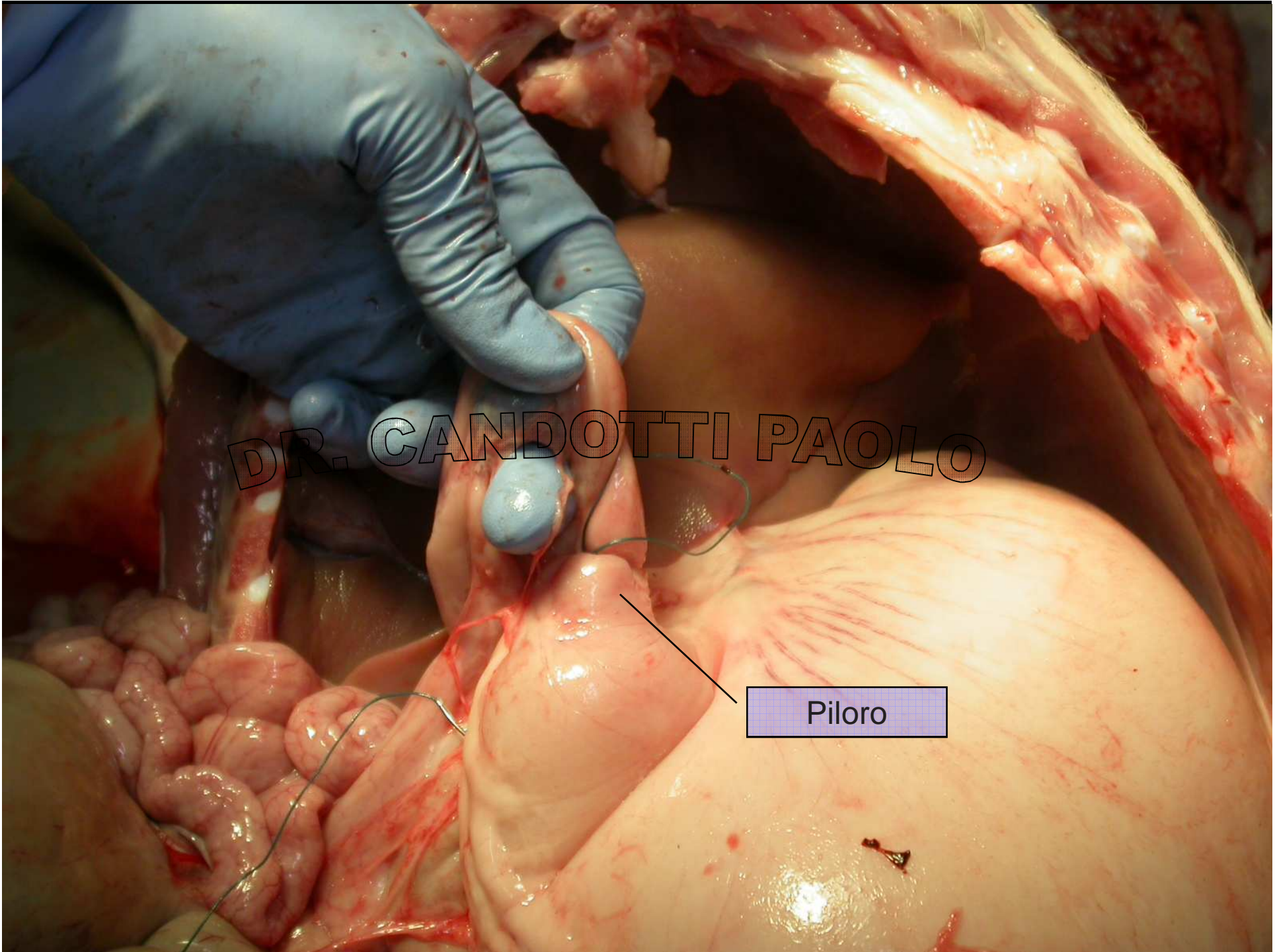
Borsina ovarica (aperta)

Vagina

DR. CANDOTTI PAOLO

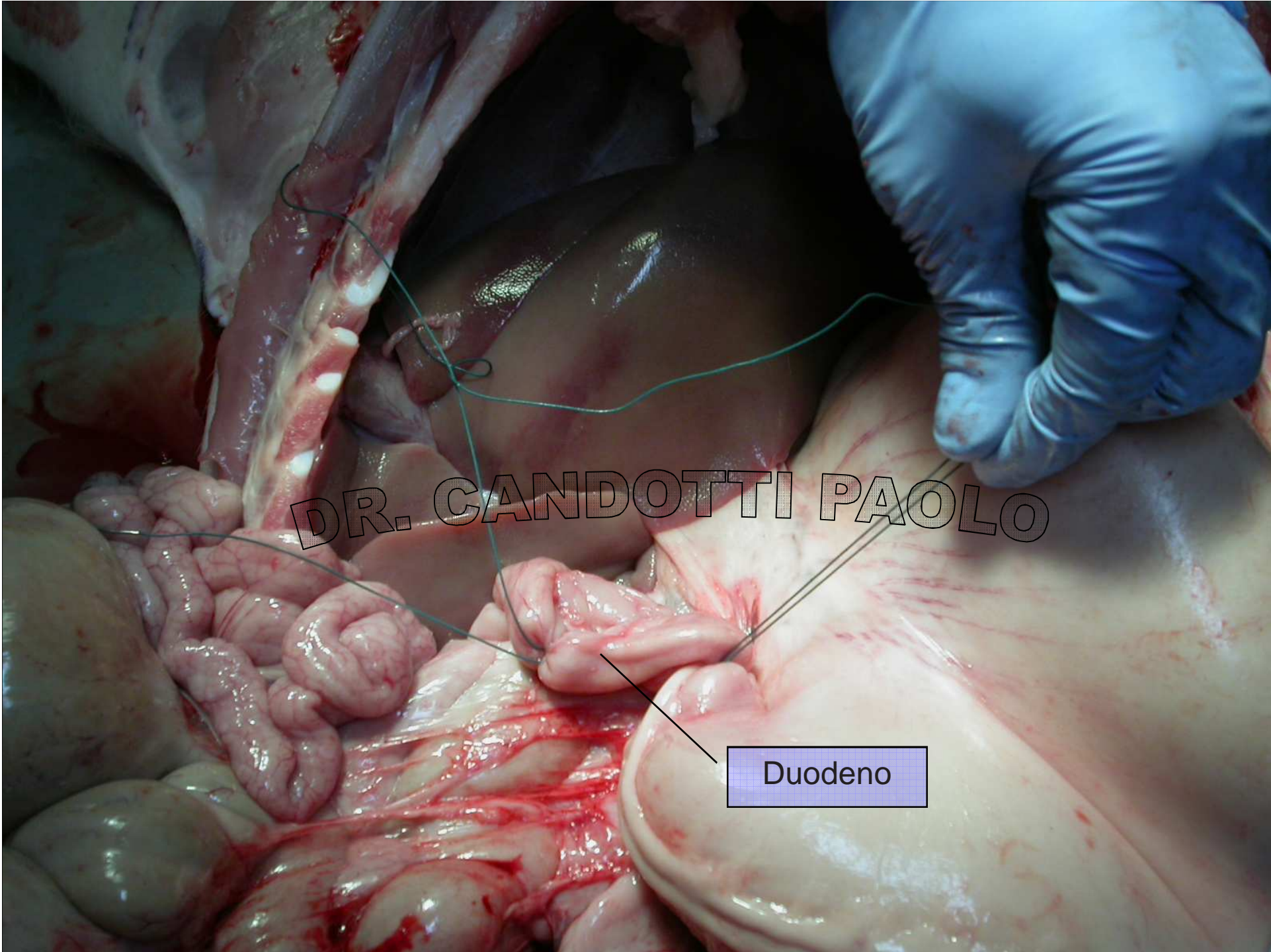
Testa del pancreas





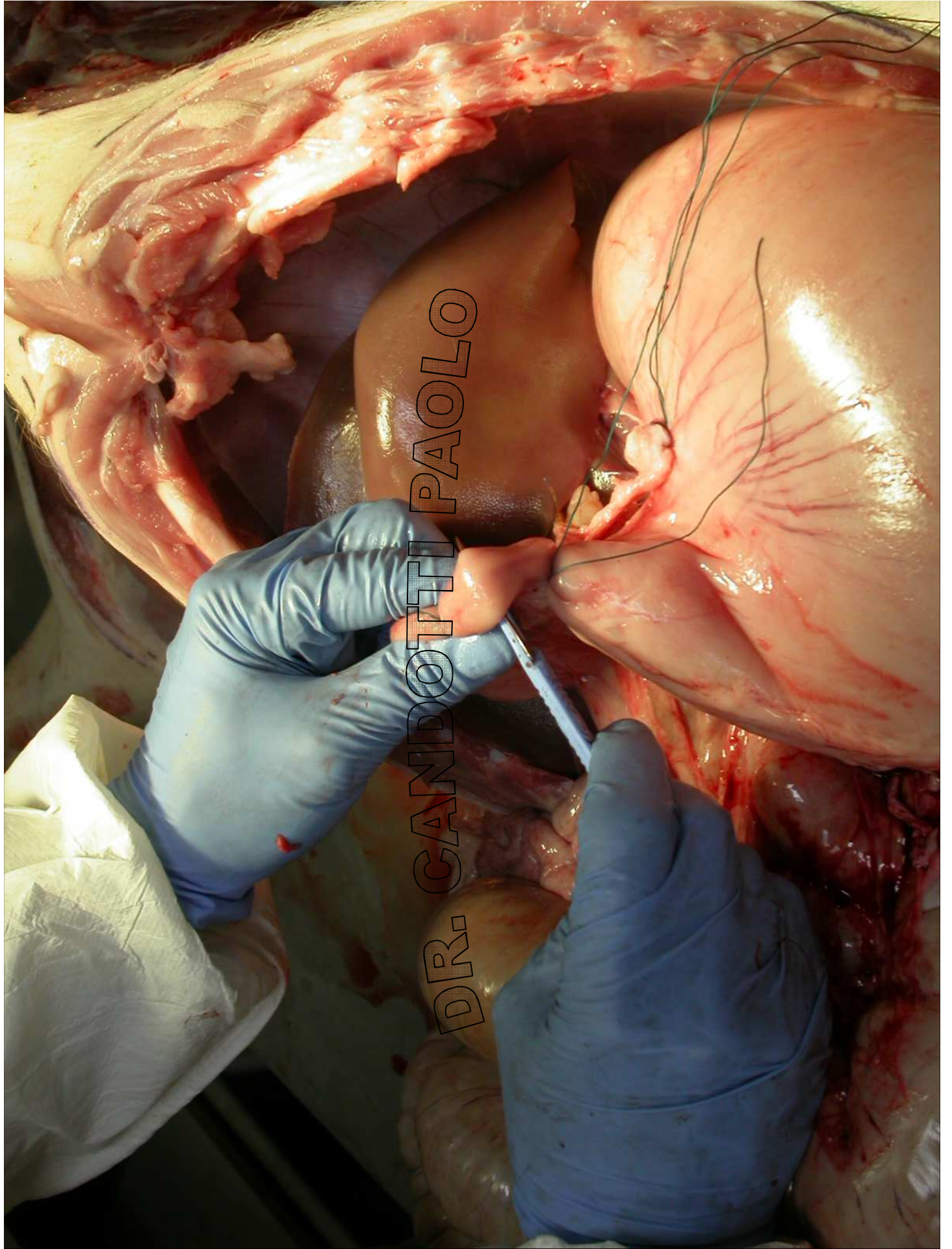
DR. CANDOTTI PAOLO

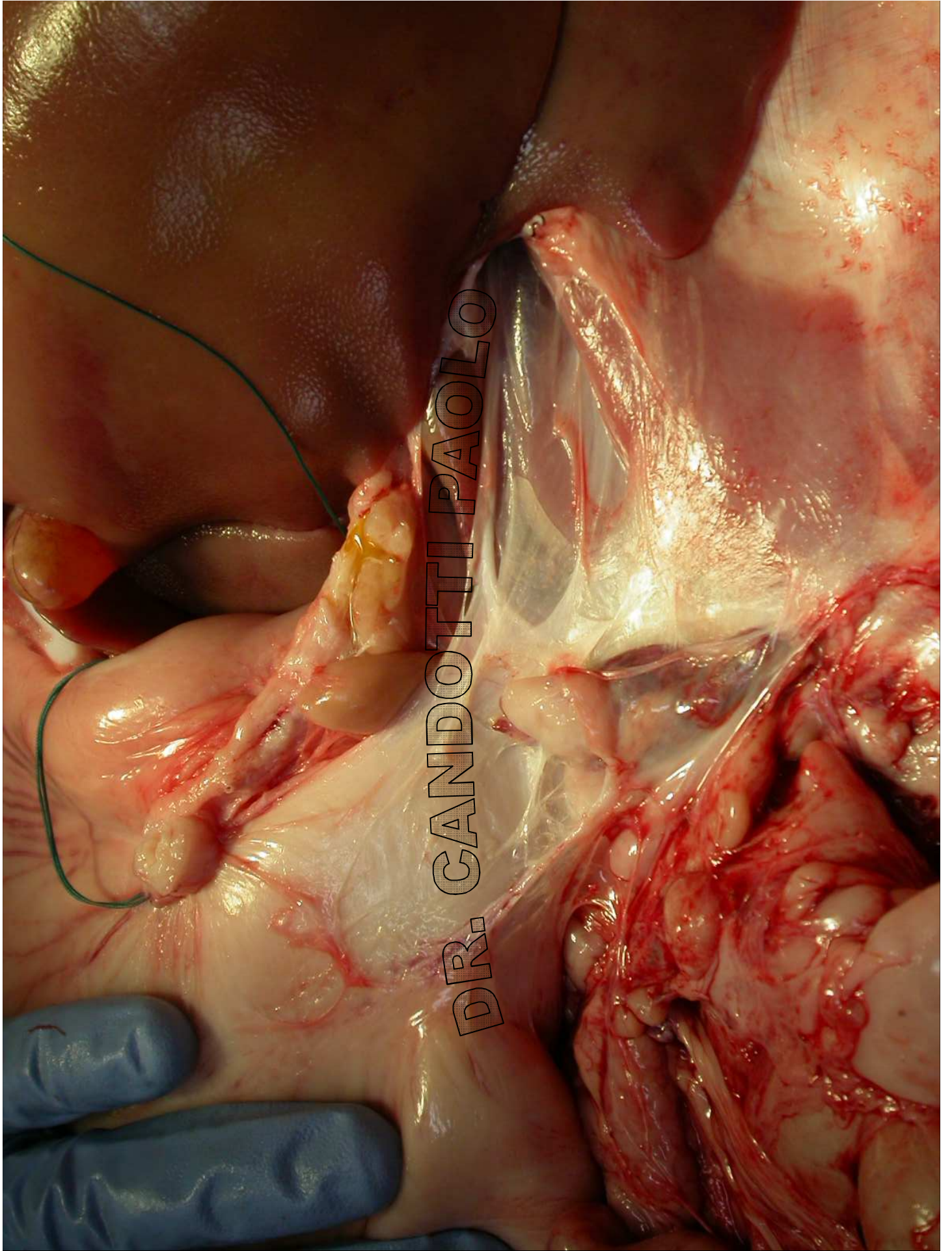
Piloro

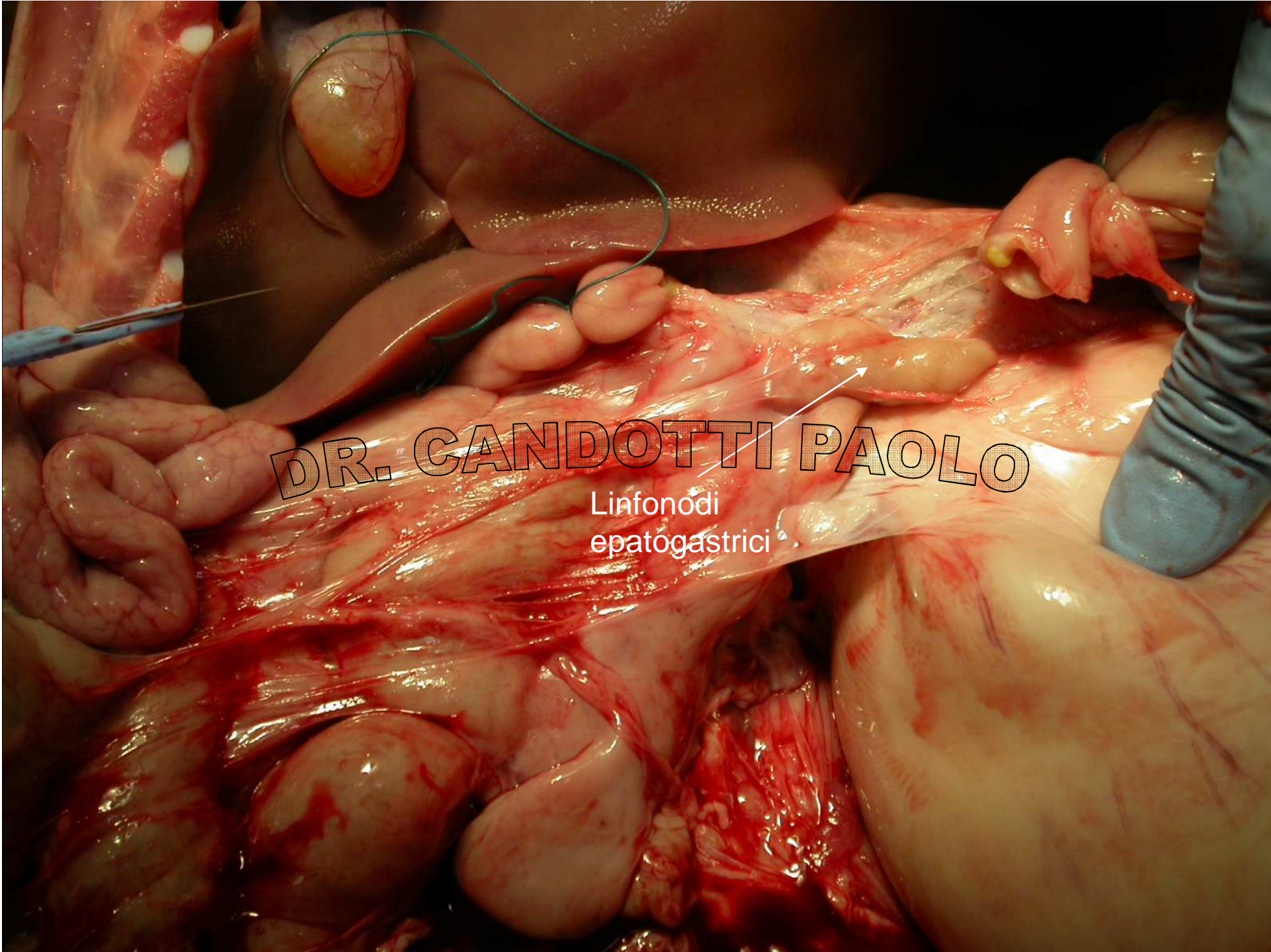


DR. CANDOTTI PAOLO

Duodeno







DR. CANDOTTI PAOLO

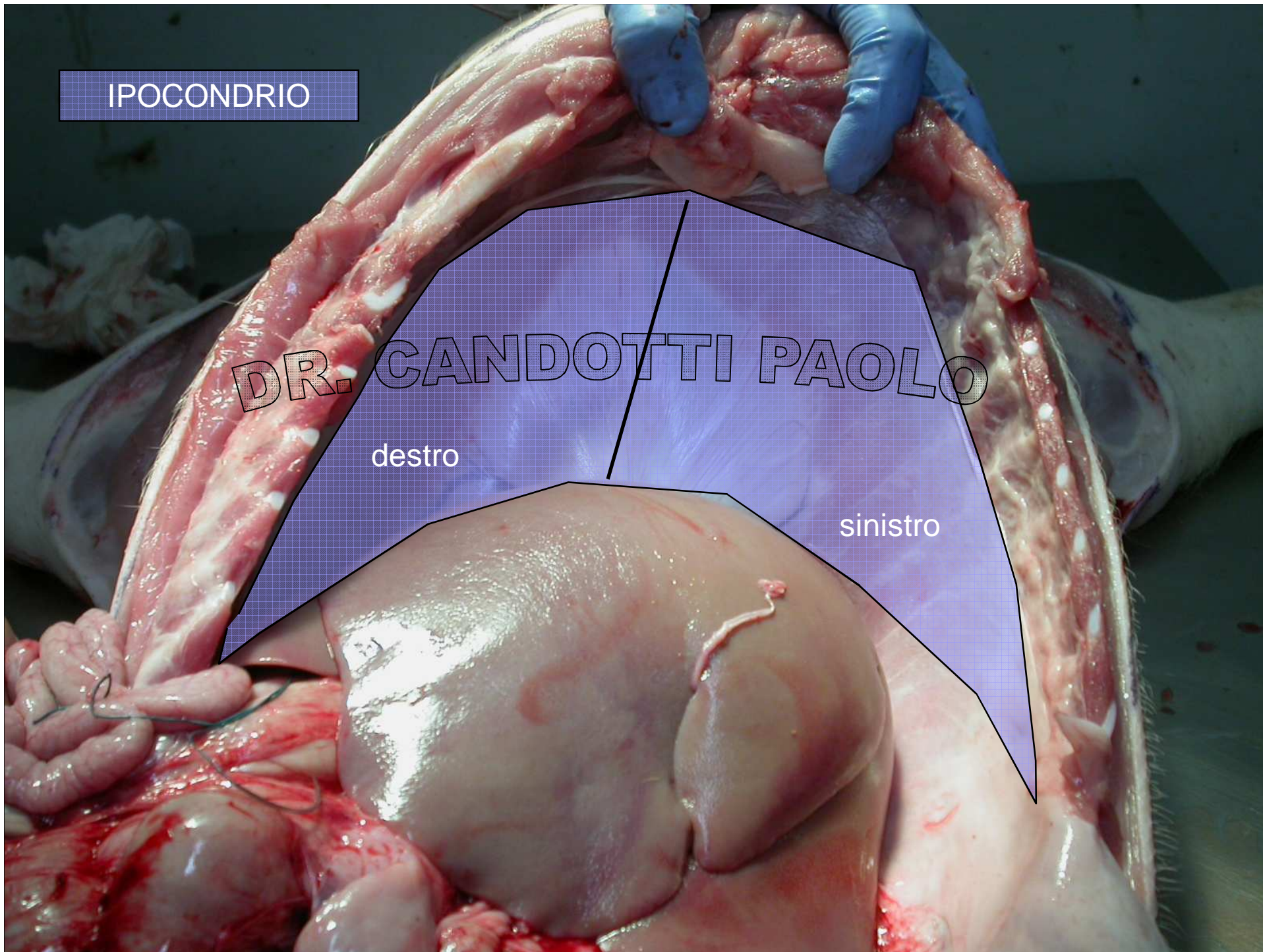
Linfonodi
epatogastrici

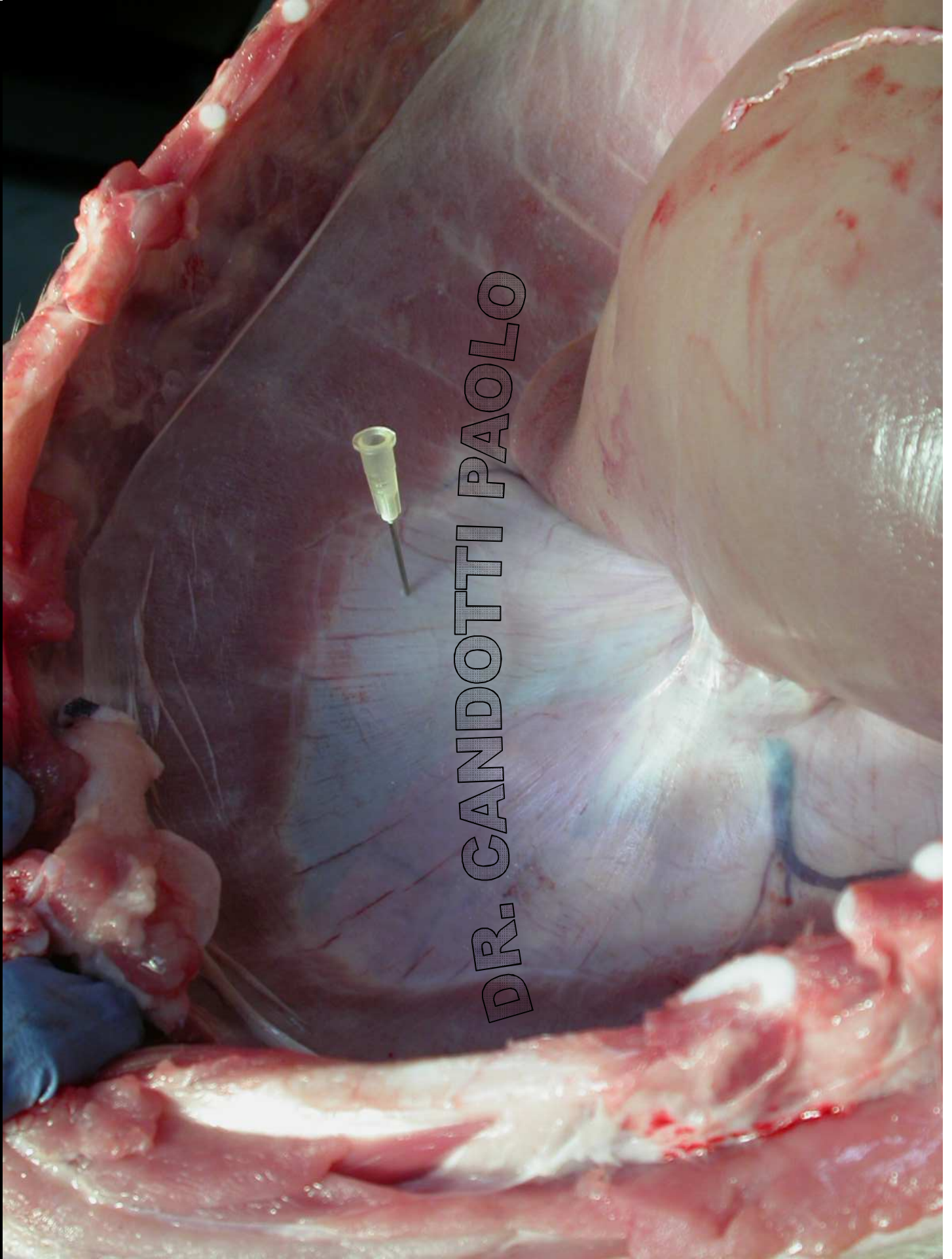
IPOCONDRI

DR. CANDOTTI PAOLO

destro

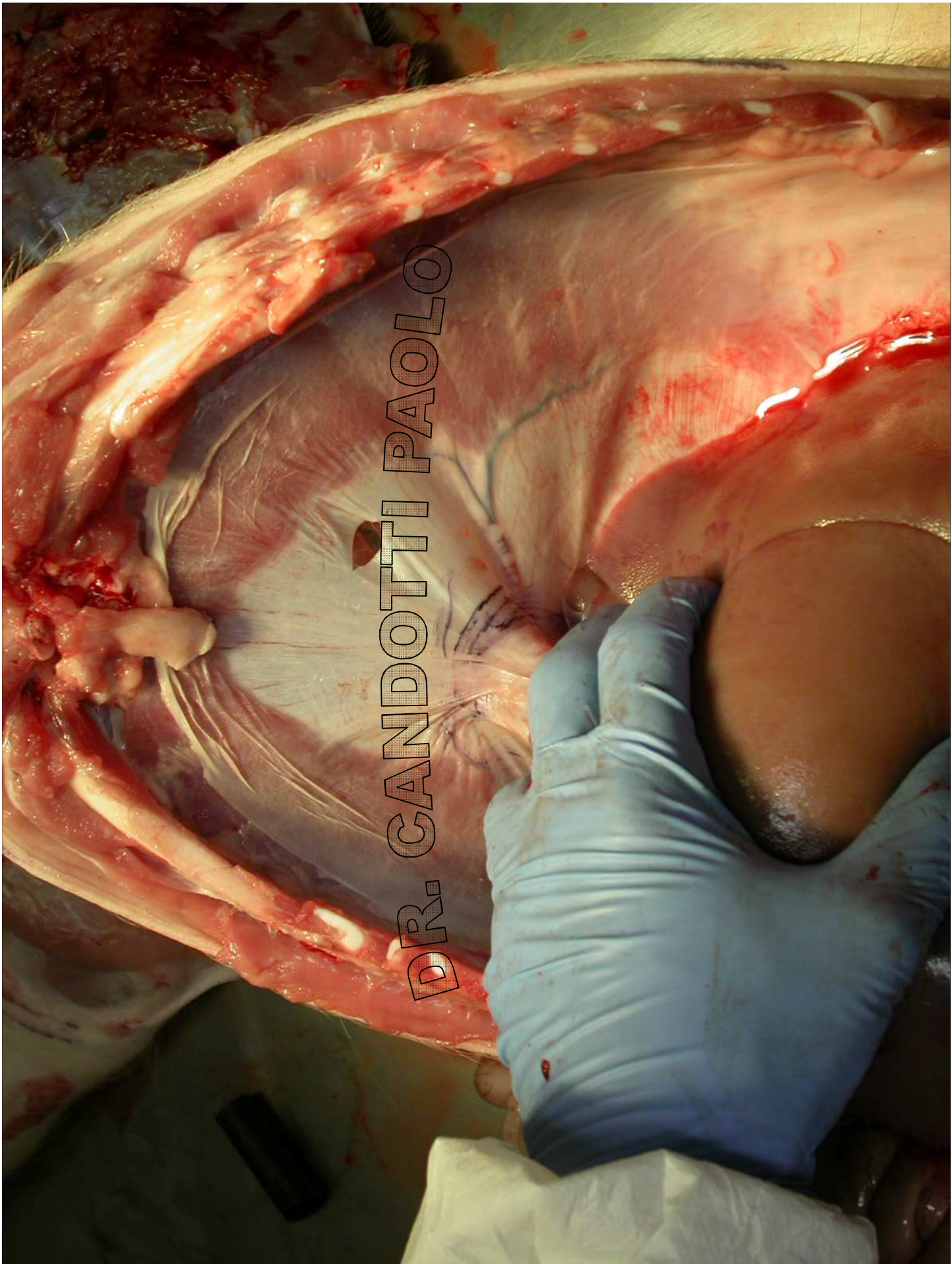
sinistro





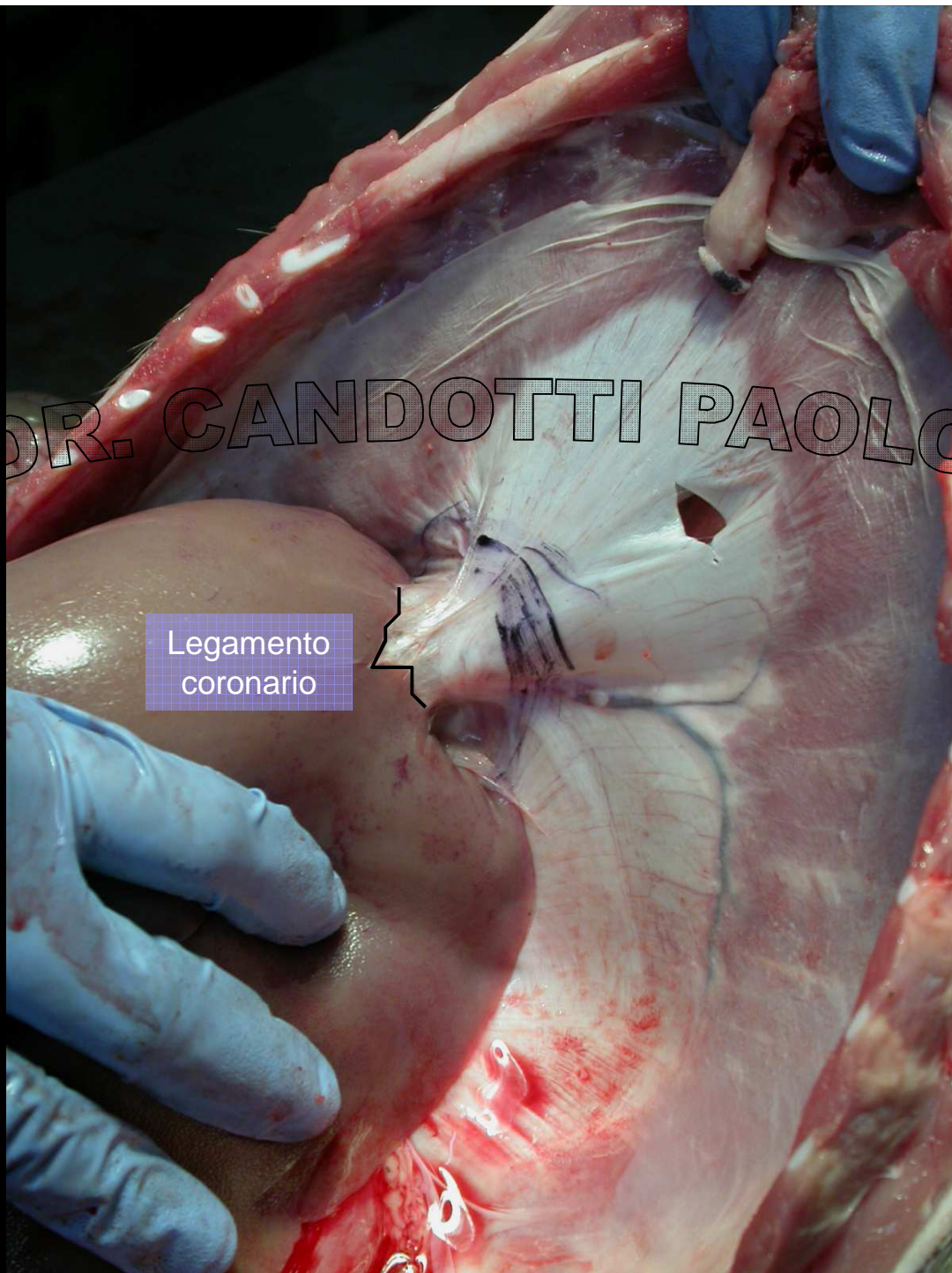
DR. CANDOTTI PAOLO

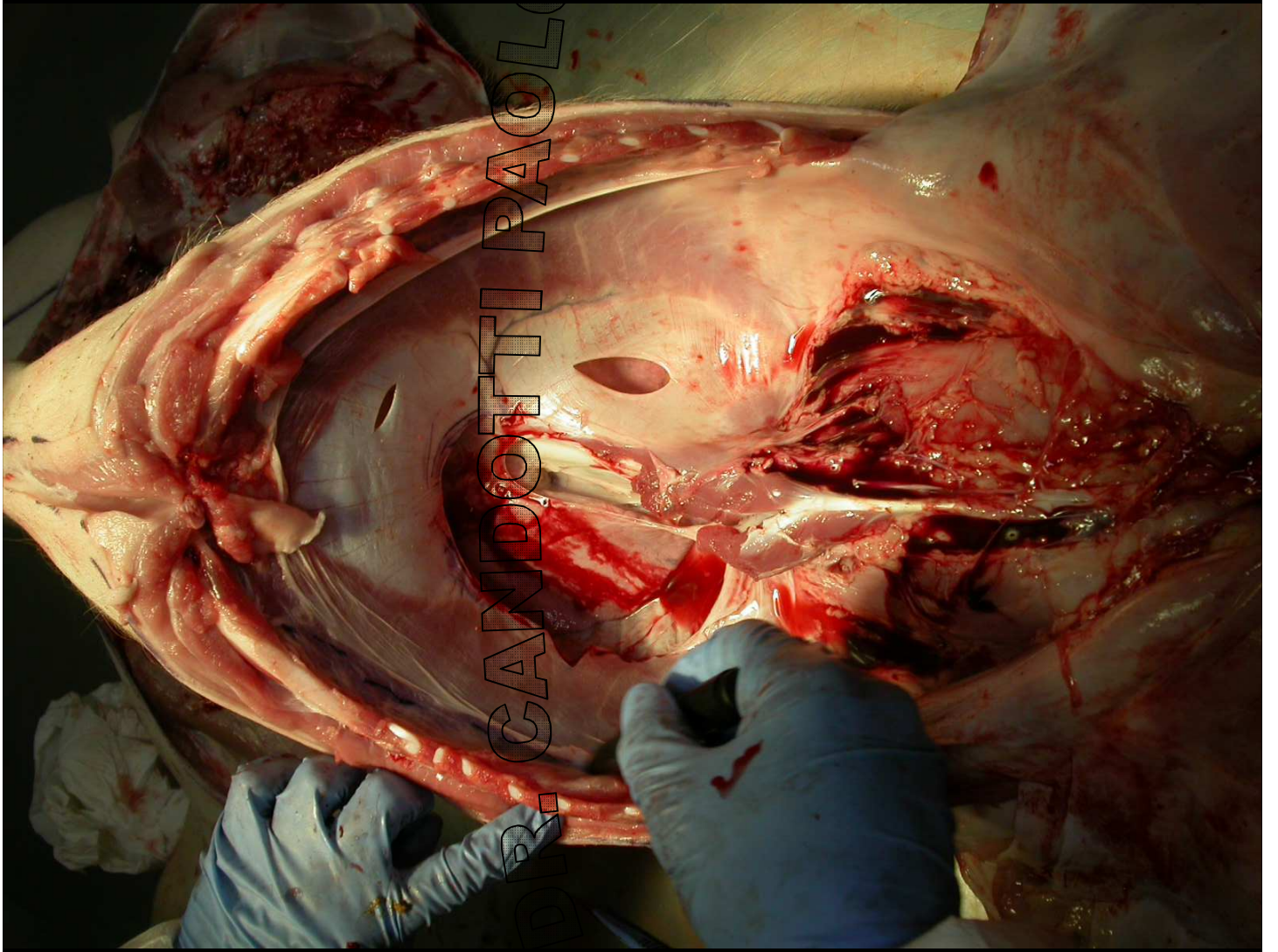
DR. CANDOTTI PAOLO

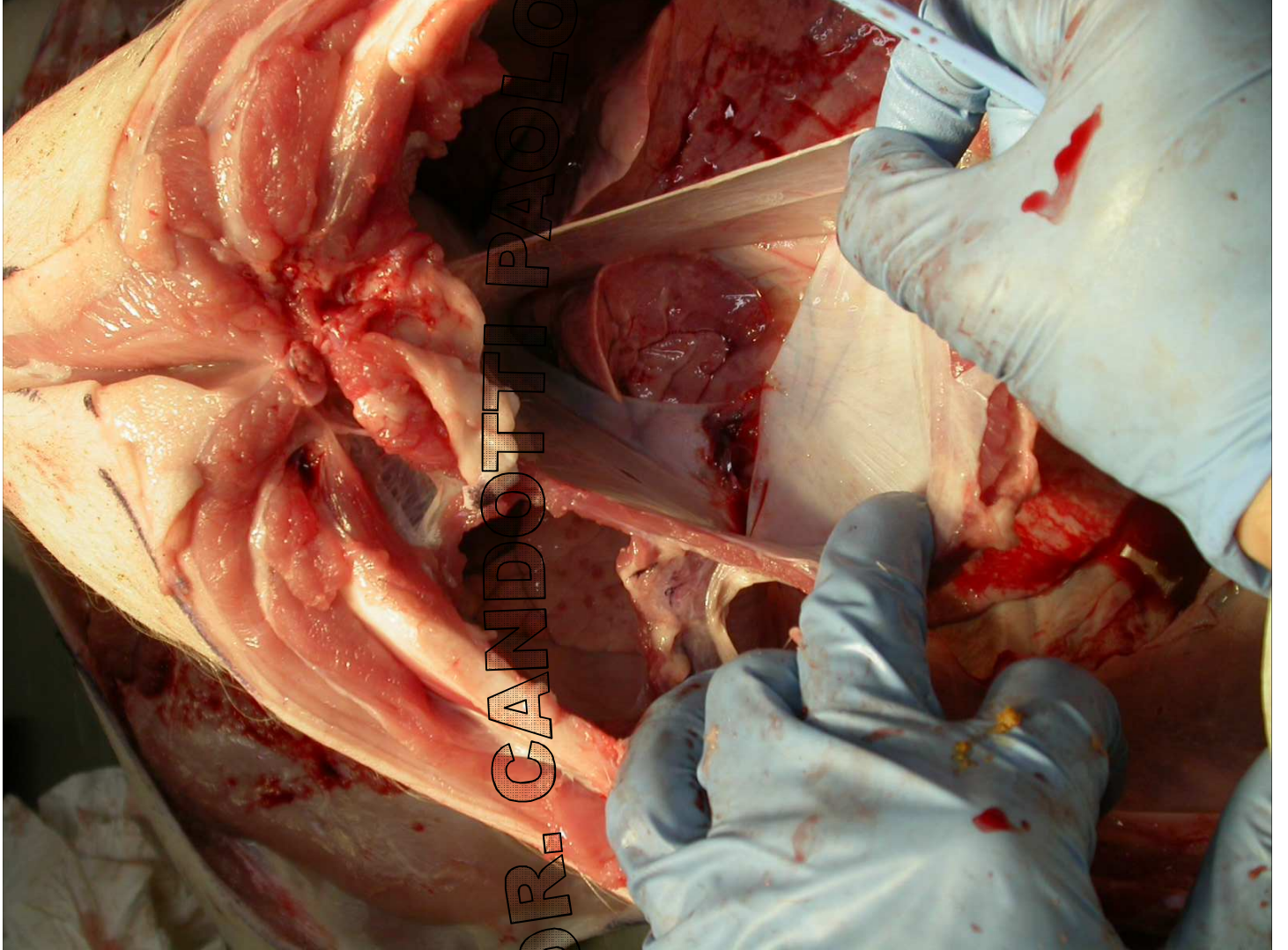


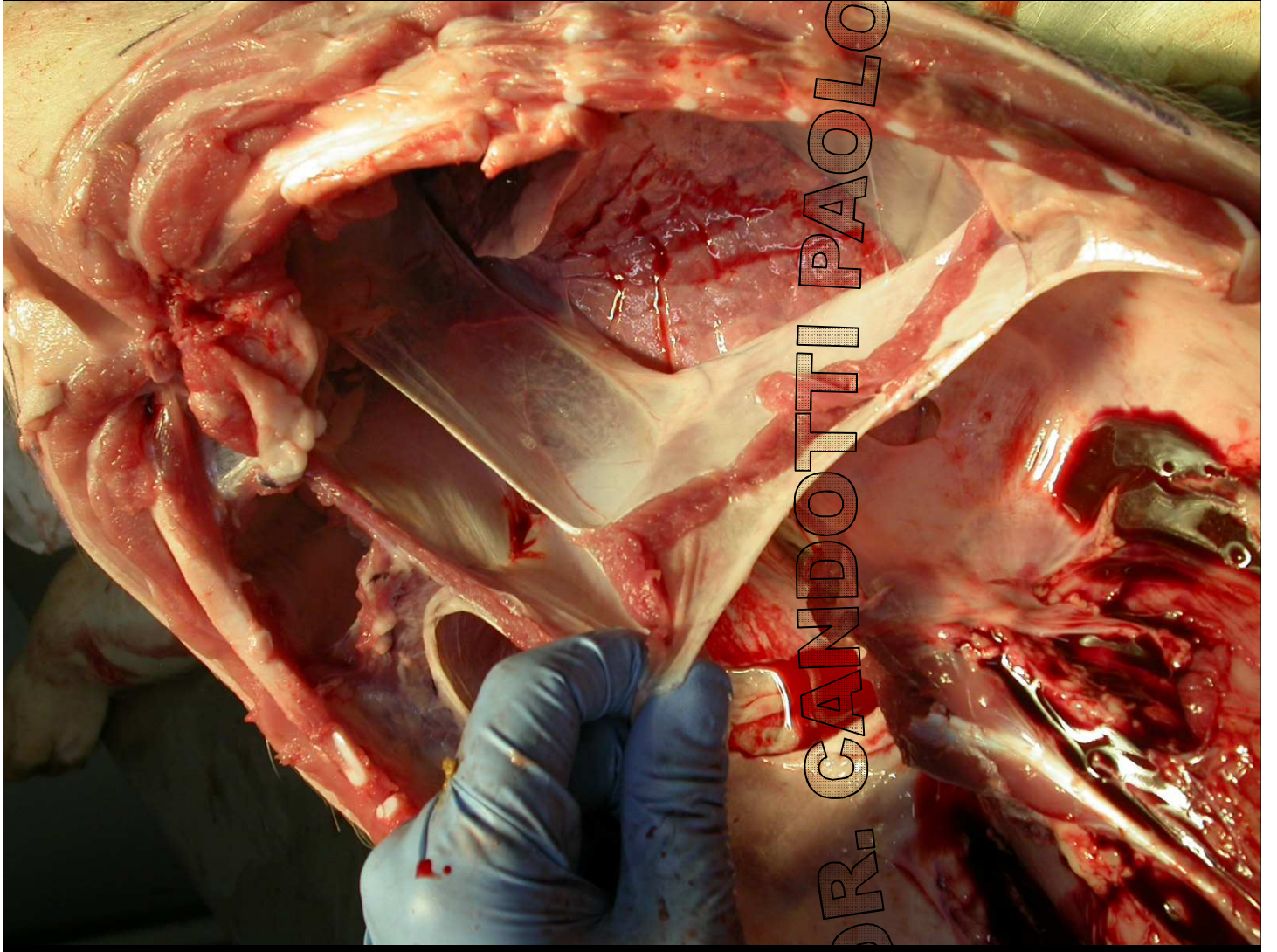
DR. CANDOTTI PAOLO

Legamento
coronario









DR. CANDOTTI PAOLO